

OUTCOME OF CANALICULAR REPAIR: OUR EXPERIENCE AT HAYATABAD MEDICAL COMPLEX PESHAWAR

Naz Ullah¹, Samina Karim^{*2}, Romaisa³, Arooj⁴, Rashed⁵

¹ Associate Professor Department of Ophthalmology Hayatabad Medical Complex Peshawar

^{*2} Assistant Professor, Department of Ophthalmology Hayatabad Medical Complex Peshawar

^{3,4,5} Postgraduate Resident Department of Ophthalmology Hayatabad Medical Complex Peshawar

Corresponding Author:

Dr. Samina Karim

Assistant Professor Department of Ophthalmology Hayatabad Medical Complex Peshawar

drsaminakarim@yahoo.com

ABSTRACT

Background: Canalicular injuries, which may occur due to facial trauma, surgical procedures, remain a considerable source of difficulty in ophthalmic practice, as they play an integral role in tear drainage. Failure to repair these injuries in a time-efficient and effective manner can result in chronic epiphora, infections, and ocular surface complications, negatively affecting a patient's quality of life. Surgical technique has evolved, with improved outcomes reflecting the usability of monocanalicular & bicanalicular stenting; however, variability in success rates and complications remain evident throughout the literature.

Objective: To evaluate the outcomes of canalicular repair in a tertiary care setting, focusing on success rates, complications, and factors influencing prognosis.

Material & Methods: This prospective observational study was carried out in the Ophthalmology Unit of Hayatabad Medical Complex, Peshawar, from January 1st 2021 to November 30th 2024. Study objective: To assess outcomes of canalicular repair in patients with canalicular injuries. The cohort comprised 34 patients aged between 05–60 years with canalicular injuries who underwent surgical repair during the study period.

Results: Primary anastomosis with canalicular stenting (using common silicon DCR tubes, "Bodkin tube") was the technique of choice for all the cases. Majority of the patients were male (73.5%, n=25), and the remaining were female (26.5%, n=9). The most common cause of canalicular injury was facial trauma (88.2%, n=30), followed by animal bites (5.9%, n=2). The remaining 02 cases was due to other injuries. Most injuries involved the lower canaliculus (76.5%, n=26), upper canaliculus was involved in (17.6%, n=6), while both the canaliculi were involved in the remaining 2 (5.9%) cases.

Conclusion: Early surgical intervention of canalicular injuries yields a 97% success rate with canalicular stenting. Timely intervention is essential; repairs completed within 48 hours significantly improves the outcome. The low rate of complications speaks to the safety of these techniques.

Keywords: Canalicular injuries, Lacrimal drainage system, Monocanalicular stenting, Bicanalicular intubation, Epiphora

The Research of Medical Science Review

INTRODUCTION

Canalicular injuries, although not frequent, are one of the most challenging injuries facing an ophthalmic surgeon, given the canaliculi's importance in tear drainage. These structures are part of the lacrimal drainage system and carry tears from the eye surface to the nasolacrimal duct. Any disruption can result in chronic epiphora, infection, and considerable patient discomfort, rendering prompt and expeditious repair crucial [1]. The majority of canalicular injuries are due to facial trauma (i.e., sharp or penetrating wounds); however, they can also happen due to animal bites and surgical procedures [2].

The success of canalicular repair is very much time-sensitive, where early repair (preferably within 48 hours) has been associated with the best outcomes [3]. This means that any fibrosis and canalicular stenosis that occurs due to delayed treatment makes it more difficult for the repair process to take place, decreasing the likelihood of success. Established surgical options for treating these injuries vary from primary anastomosis to more complex approaches that facilitate patency during healing using stents or tubes [4,5].

The management of canalicular lacerations remains controversial, with various recommendations in the literature [6,7]. An indwelling canalicular stent is often used to align the transected ends and maintain luminal patency during healing. Our preferred approach involves repairing the transected canaliculus using a common silicone DCR tube to intubate both the upper and lower canaliculi effectively [8].

In monocanalicular repair either the upper or lower canalicular can be intubated, depending upon location of the injury or obstruction. Other flexible stents that are used at monocanalicular intubation are Mini Monaka, Viers rod and Johnson wire. The most familiar of these is the Mini Monaka stent because of its ease of insertion and efficiency of use. The advantage of this type of stent is that it has cap at one end which prevent it from moving around during the healing period and thus ensures better result [Fig-1].

Bicanalicular repair is performed by placing stents into both the upper and the lower canaliculus to ensure the patency of the lacrimal drainage system [Fig-2]. With a DCR the two open ends are sutured end to end using 6/0 nylon sutures and knots trimmed and buried towards the common canaliculus and the lacrimal sac [9]. In the other approach, the tube ends are exteriorized through the nasolacrimal duct (NLD) and retrieved and tied through the nasal cavity [Fig-3]. When combined with DCR, the process involves making a new pathway for drainage, and the ends of the tubes passed via the NLD and secured on the nose to ensure stabilization and drainage [Fig-4]. We aim to present our results in the context of the current literature to contribute to the discussion of the optimal canalicular injury management.




Figure-1: Monocanalicular intubation

Figure-2: Bicanalicular intubation



Figure-3: Bicanalicular repair without DCR

Figure-4: Bicanalicular repair with DCR

The Research of Medical Science Review

MATERIAL AND METHODS

This prospective observational study was carried out in the Ophthalmology Unit of Hayatabad Medical Complex, Peshawar, from January 1st 2021 to November 30th 2024. Study objective: To assess outcomes of canalicular repair in patients with canalicular injuries. The cohort comprised 34 patients aged between 05–60 years with canalicular injuries who underwent surgical repair during the study period. Patients were selected consecutively, and inclusion criteria included any patient meeting the specified age range diagnosis of a canalicular injury by-trauma, surgery, or other causes. Exclusion criteria were: patients with a pre-existing disease of the lacrimal drainage system, sever ocular surface disease, or prior canalicular surgery. Data were collected prospectively from patient medical records and surgical reports. Preoperative assessments included a thorough detailed patient history, ophthalmic examination, and examination with slit lamp. Each patient provided informed consent before participation in the study.

The choice of surgical technique depended on the extent of the injury and the surgeon's expertise. For most patients, in our setup bicanalicular intubation with "Bodkin tube" was performed, due to cost effectiveness and frequent availability of the tubes (Figure 5-8). All procedures were performed under general anesthesia with sedation, following standard aseptic surgical protocols.

Postoperative care included topical antibiotics and corticosteroids to prevent infection and inflammation. Patients were monitored regularly at 1 week, 1 month, 3 months, and 6 months post-surgery for signs of complications such as infection, canalicular stenosis, or stent displacement. The canalicular function was evaluated by

- a) history from patient-reported outcomes related to epiphora and overall comfort.
- b) by examining the lid and punctai position, tear film & performing regurge test.

The main outcome was the rate of success of canalicular repair, defined as restoration of sufficient tear drainage without excessive epiphora with good lid position. Secondary outcome parameters were complication rate, and factors affecting prognosis, i.e. the timing of the intervention and type of surgical technique used. The statistical software package SPSS 23.0 was used to analyze data. Descriptive statistics were used to characterize patient demographics, including age and sex, and nature of injury. Success rates of canalicular repair were determined and relationships between patient characteristics, surgical technique, and outcome were examined using suitable statistical tests which included chi-square tests and logistic regression analysis. Statistical significance was defined as $p \leq 0.05$.

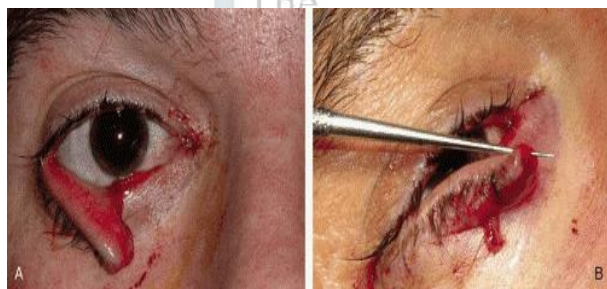

Figure-5: Lower canalicuar injury

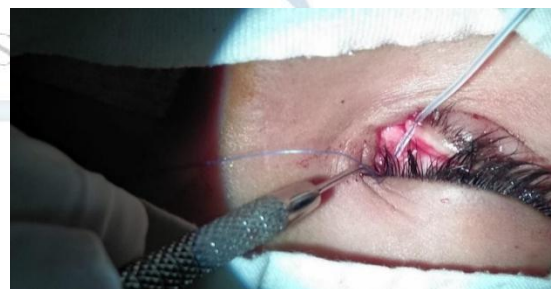

Figure-6: Repair with Bodkin Tube

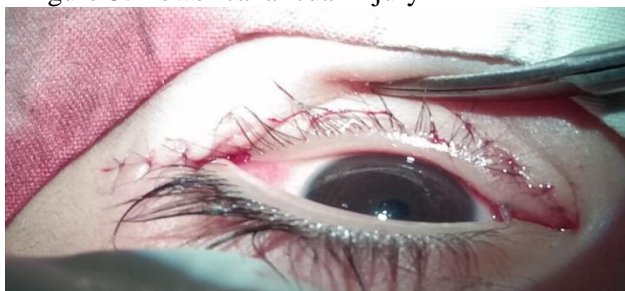


Figure-7

(end to end suturing using 5/0 nylon sutures, knots trimmed aned buried towards the common canaliculus and the lacrimal sac)

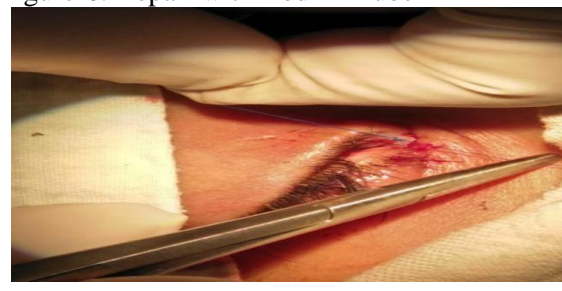

Figure-8:

The Research of Medical Science Review

RESULTS

A total of 34 patients were included in the study, with ages ranging from 05 to 60 years (mean age: 39.2 ± 13.5 years). The majority of the patients were male (73.5%, n=25), and the remaining were female (26.5%, n=9). The most common cause of canalicular injury was facial trauma (88.2%, n=30), followed by animal bites (5.9%, n=2). The remaining 02 cases was observed due to other injuries. Most injuries involved the lower canaliculus (76.5%, n=26), upper canaliculus was involved in (17.6%, n=6), while both canaliculi was injured and lacerated in the remaining 2 (5.9%) of cases. Table-1

Table-1: Patient Demographics and Injury Characteristics

Characteristic	Number	percentage
Age		
Age range	5 to 60 years	
Mean \pm SD	39.2 ± 13.5 years	
Gender		
Male	25	73.5%
Female	9	26.5%
Cause of Injury		
Facial Trauma	30	88.2%
Animal bites	2	5.9%
Other	2	5.9%
Location of Injury		
Lower Canaliculus	26	76.5%
Upper Canaliculus	6	17.6%
Both canaliculi	2	5.9%

Primary anastomosis with bicanalicular stenting (using common silicon DCR tubes, “Bodkin tube”) was the technique of choice for all the cases. The mean time from injury to surgical repair was 28 ± 11.2 hours, with (94.1%, n=32) of patients undergoing repair within 48 hours, while the rest 2(5.9%) received repair beyond 48 hours. Notably, one case (2.9%) was repaired after 2 weeks, and another after 2 months due to delayed presentation to the outpatient department (OPD) (Table-2). Table-2

Table-2: Surgical technique & time to repair

Outcome	Number	Percentage
Technique		
Bicanalicular intubatioin	34	100%
Time to repair		
within 48 hours	32	94.1%
After 2 weeks	1	2.9%
After 2 months	1	2.9%

Mean time from injury to intervention: 28 ± 11.2 hours

The overall success rate of canalicular repair was 97% (n=33), with successful restoration of tear drainage and no significant epiphora reported by these patients during follow-up. In only one case failure was observed due to watering and epiphora. Postoperative complications were minimal, with corneal ulceration observed in only 1 case (3%). Patients who underwent early repair (within 48 hours) demonstrated a higher success rate of 100% (33/33), while those with delayed repair (>48 hours) had a success rate of 50% (1/2). Table-3

The Research of Medical Science Review

Table-3: Outcome of the study.

Outcome	Number of Patients	Percentage (%)
Successful Repair	33	97%
Failed	1	3%
Complications (n=1)		
Corneal ulcer	1	3%
Success rate by timing		
≤ 48	33	100%
beyond 48 hours	1	50%

Discussion

Injuries to the canaliculi have posed a problem in ophthalmic surgery for many years as the lacrimal drainage system is very delicate and the canaliculi are very important for the drainage of tears. These injuries have been managed with various techniques since they were first recognized, and unfortunately, many of the early techniques relied almost exclusively on primary repair without any stenting, which led to some of the highest failure rates seen due to canalicular stenosis. As fixation techniques declined in the 1960s, stents were increasingly adopted to support both under and over repairs of the canalicular system, enhancing procedural outcomes. In the following decades, canalicular repair as a therapeutic procedure gained increasing popularity, with monocanicular and bicanicular stents significantly reducing postoperative stenosis and optimizing functional outcomes [11]. In recent years, advancements in surgical management, supported by improved imaging and minimally invasive techniques, have further revolutionized the treatment of these injuries. The overall canalicular repair success rate in our study was 97% with the majority of patients having successful restoration of tear drainage with no significant epiphora. This is comparable to other studies that have shown success rates of 85% to 95% in similar populations [12,13].

This study presents valuable information regarding the management and outcomes of canalicular injuries. In total, 34 patients were included with the majority (73.5%) of patients being male with a mean age of 39.2 ± 13.5 years. Facial trauma was the most common reason for canalicular injury (67.6%) and was in line with previous literature focused upon blunt trauma as dominant in these cases [14]. Significantly, the most affected area was the lower canaliculus (76.5%) with the fact that the lower canaliculus is anatomically predisposed to external insult because of its location.

Primary anastomosis with bicanicular stenting (using common silicon DCR tubes, “Bodkin tube”) was the technique of choice for all the cases, due to cost effectiveness and easy availability of the stents in our setup. These observations are consistent with the findings of Alam MS et al, who observed notable efficacy using these techniques in reaching both anatomical and functional success [15].

Early repair within 48 hours of the trauma had a 100% success rate, whereas delayed repair had a 50% success rate, indicating that the time of the surgical surgery was a key impact in the outcome. These results support those of Bai F et al, who found that early intervention maximizes tear drainage repair and reduces fibrosis [16]. The average repair duration of 28 ± 11.2 hours emphasizes the necessity of prompt surgical intervention to maximize better outcomes. The minimal complication rate, with only one case of corneal ulceration (3%), reflects the safety of these techniques. Similar findings were observed by Mansoor H et al, who reported comparable success rates with minimal adverse events [17].

Despite these promising results, the study has certain limitations. First, the sample size was relatively small, which may limit the generalizability of the findings. Second, the study lacked a long-term follow-up period to evaluate the durability of the repair and recurrence of epiphora over time. Lastly, the study was conducted in a single center, which may not reflect outcomes in different clinical settings with varied expertise and resources.

The Research of Medical Science Review

CONCLUSION

The present study results underscore high success rates (97%) of canalicular repair performed with primary anastomosis using bicanalicular stenting technique that was associated with cost effectiveness and low complication rates. Facial trauma was the most common cause for canalicular injury. Early surgical repair during the first 48-hours was linked with improved clinical benefits, which underscores the crucial importance of timely intervention. Our data supports the timely surgical intervention, proper surgical management, and postoperative care are integral for achieving optimal functional outcomes with canalicular injuries.

REFERENCES

- Junjun Han, Hongling Chen, Tian Wang, Xianliang Zhang. A case series study of lacrimal canalicular laceration repair with the bi-canalicular stent. *Gland Surgery* 2022; 11(11): 1801-1807.
- Lin CH, Wang CY, Shen YC, et al. Clinical Characteristics, Intraoperative Findings, and Surgical Outcomes of Canalicular Laceration Repair with Monocanalicular Stent in Asia. *J Ophthalmol* 2019;2019:587.
- Chu YC, Wu SY, Tsai YJ, Liao YL and Chu HY. Early versus late canalicular laceration repair outcomes. *Am J Ophthalmol*. 2017;182:155-159.
- Raj A, Thakur S, Arya KS, Kesarwani P and Sinha U. Canalicular lacerations in a tertiary eye hospital: Our experience with monocanalicular stents. *Rom J Ophthalmol*. 2020;64(2):146-152.
- Singh M, Gautam N, Ahir N, Kaur M. Is the distance from punctum a factor in the anatomical and functional success of canalicular laceration repairs? *Indian Journal of Ophthalmology*. 2017; 65(11):1114-9.
- Birjees Hakak1, Junaid S Wan. Surgical outcomes of canalicular tear repair with self-retaining Mini-Monoka stent in a tertiary care hospital in Kashmir in North India. *Asian Journal of Medical Sciences* 2022; 13(11): 214-218.
- Singh S, Ganguly A, Hardas A, Tripathy D and Rath S. Canalicular lacerations: Factors predicting outcome at a tertiary eye care centre. *Orbit*. 2017;36(1):13-18.
- Guo T, Qin X, Wang H, et al. Etiology and prognosis of canalicular laceration repair using canalicular anastomosis combined with bicanalicular stent intubation. *BMC Ophthalmol* 2020;20:246.
- Ducasse A, Arndt C, Brugniart C, et al. Lacrimaltraumatology. *J Fr Ophtalmol* 2016;39:2.
- Peng W, Wang Y, Tan B, et al. A new method for identifying the cut ends in canalicular laceration. *Sci Rep* 2017;7:43325.
- Yan CF. Efficacy of double lacrimal duct placement with mitomycin in the treatment of recurrent tear duct membrane closure. *Journal of Practical Medical Techniques* 2021;28:80-1.
- Kim T, Yeo CH, Chung KJ, et al. Repair of Lower Canalicular Laceration Using the Mini-Monoka Stent: Primary and Revisional Repairs. *J Craniofac Surg* 2018;29:949-52.
- Chu YC, Wu SY, Tsai YJ, et al. Early Versus Late Canalicular Laceration Repair Outcomes. *Am J Ophthalmol* 2017;182:155-9.
- Nayana P, Shruti S, Amol G and Swaranjali G. Outcomes of canalicular tear repair using a mini-monoka silicone stent: Results from a tertiary care centre. *Int J Ocular Oncol Oculoplasty*. 2017;3(4):261-264.
- Alam MS, Mehta NS, Mukherjee B. Anatomical and functional outcomes of canalicular laceration repair with self-retaining mini-MONOKA stent. *Saudi J Ophthalmol* 2017;31:135-9
- Bai F, Tao H, Zhang Y, et al. Old canalicular laceration repair: a retrospective study of the curative effects and prognostic factors. *Int J Ophthalmol* 2017;10
- Mansour HO, Ramadan Ezzeldin E. Bicanalicular Annular Stent Compared with Bicanalicular Nasal Intubation in Management of Traumatic Lower Canalicular Laceration. *Clin Ophthalmol* 2022;16:213-22.