

SCREENING MAMMOGRAPHY PERFORMANCE OF 2D DIGITAL MAMMOGRAPHY VERSUS BREAST ULTRASONOGRAPHY IN WOMEN WITH DENSE BREAST

Sayedra Kiran Aftab^{*1}, Dr Saima Haider², Dr Tayyab Mughal³, Shamsa Batool⁴,
Dr Syeda Maryam Tirmizi⁵, Dr Erum Saba⁶

^{*1,2}Superior University Lahore

³Radiologist FCPS Islamabad Diagnostic Centre Sialkot.

⁴Forman Christian College A Chartered University

⁵Post Graduate Trainee Diagnostic Radiology PAF Hospital Islamabad / Fazaia Medical College
Islamabad

⁶Radiology Department Registrar Dr. Ziauddin University Hospital

^{*1}Kiran2ajk@gmail.com, ²saimahaider@gmail.com, ³Tayyabmughal7@gmail.com,
⁴shamsabatool007@gmail.com, ⁵maryamtirmizi@gmail.com, ⁶erumradiology@gmail.com

DOI: <https://doi.org/10.5281/zenodo.14716044>

ABSTRACT

This study aimed to evaluate and compare the performance of 2D digital mammography and breast ultrasonography in detecting breast cancer among women with dense breast tissue, categorized as BI-RADS C (heterogeneously dense) and D (extremely dense). Dense breast tissue presents significant challenges for accurate mammographic detection, necessitating the investigation of alternative or supplementary screening approaches. A cross-sectional study design was implemented, recruiting participants from imaging centers. Eligible women with dense breasts underwent both 2D digital mammography and breast ultrasonography after providing informed consent. The primary outcomes assessed were breast cancer detection rates, false-positive rates, sensitivity, and specificity of each screening modality. Data were collected through medical records and imaging results, with follow-up evaluations to capture subsequent diagnostic interventions. The comparative analysis focused on the accuracy of each method in identifying breast abnormalities within dense tissue, emphasizing true-positive rates, false-positive rates, sensitivity, and specificity. The findings revealed that both 2D digital mammography and breast ultrasonography offer valuable contributions to breast cancer detection, particularly when used in combination. While mammography demonstrated a higher false-positive rate and was associated with physical discomfort, ultrasonography resulted in lower patient satisfaction and heightened emotional distress, especially among high-risk individuals. Despite these limitations, integrating both modalities improved early detection rates and enhanced overall patient outcomes. The study underscores the importance of a tailored, multimodal approach to breast cancer screening for women with dense breast tissue.

The Research of Medical Science Review

Keywords: Dense Breast Tissue, 2D Digital Mammography, Breast Ultrasonography, Breast Cancer Screening.

INTRODUCTION

Breast cancer, a common malignancy originating in breast ducts or lobules, remains one of the most prevalent cancers globally, contributing significantly to morbidity and mortality (Mesurole et al., 2021). Early detection and treatment are essential for improving survival rates and outcomes (Sarno et al., 2022). Breast cancer includes several subtypes, such as Ductal Carcinoma in Situ (DCIS), Invasive Ductal Carcinoma (IDC), Invasive Lobular Carcinoma (ILC), Triple-Negative Breast Cancer (TNBC), and HER2-positive breast cancer (Sarno et al., 2021). Risk factors include genetic mutations (e.g., BRCA1 and BRCA2), age, family history, hormonal and reproductive factors, lifestyle choices, and breast density (Upneja et al., 2022). Common symptoms include lumps, changes in breast shape or size, skin alterations, and nipple discharge.

Mammography is the primary screening tool for breast cancer, though its sensitivity diminishes in women with dense breast tissue, which contains more fibroglandular than fatty tissue, often obscuring tumors (Hossain, Nishikawa, & Lee, 2022). Breast ultrasonography (US) has emerged as a complementary tool, particularly in dense breasts. Unlike mammography, which uses X-rays, ultrasonography employs sound waves to create images without radiation exposure, improving sensitivity in dense tissue (Juybari & Khalil, 2022). However, US has limitations, including lower specificity and higher false-positive rates (Maki et al., 2023).

Magnetic Resonance Imaging (MRI) provides detailed imaging and is often used for high-risk patients. Definitive diagnosis relies on biopsy, which involves microscopic examination of tissue samples (Ezeana et al., 2022). Treatment options vary based on cancer type, stage, and genetic characteristics and include surgery, radiotherapy, chemotherapy, hormonal therapy, and targeted therapy (Gerlach et al., 2023).

Combining mammography with ultrasonography enhances breast cancer detection in dense tissue, improving sensitivity while managing trade-offs like increased false positives (Polikarpov et al., 2023). Advancements in screening and treatment have significantly improved survival rates over recent decades, emphasizing the importance of tailored, multimodal approaches for effective management and improved patient outcomes (Hogan et al., 2023).

Current research on breast cancer screening highlights several critical gaps, particularly in addressing the challenges of dense breast tissue. These include the limited performance of 2D digital mammography in dense breasts, insufficient comparative studies on mammography and ultrasonography across diverse populations, and a lack of evidence on the long-term outcomes of supplemental screening methods. Additionally, the cost-effectiveness of integrating breast ultrasound into routine screening practices remains underexplored, as do patient preferences and adherence to advanced imaging techniques.

Addressing these gaps is essential to optimize screening strategies, improve detection rates, and enhance patient outcomes. Comparative studies evaluating the relative effectiveness of mammography and ultrasound in detecting breast cancer in dense breasts are particularly needed, alongside research on the economic and clinical implications of supplemental screening. This study aims to contribute to these efforts by evaluating the performance of 2D digital mammography versus breast ultrasonography, providing insights into optimal screening strategies for women with dense breast tissue and informing future guidelines and policies.

Literature Review

Michielsen et al. (2020) conducted a prospective study involving 1,391 women with dense breasts to evaluate the impact of adding breast ultrasound to 2D digital mammography. The addition of ultrasound increased cancer detection rates from 4.2 to 8.8 per 1,000 women, demonstrating its ability to identify cancers obscured by dense tissue. However, this benefit came with a higher false-positive rate, underscoring the need for careful management of additional diagnostic testing and patient anxiety.

The Research of Medical Science Review

Ochoa-Albiztegui et al. (2020) performed a multicenter trial with 2,600 women to compare digital breast tomosynthesis (DBT), 2D mammography, and ultrasound. The study found that DBT combined with 2D mammography identified 40% more cancers than 2D mammography alone. The inclusion of ultrasound further enhanced detection rates, highlighting the value of a multimodal approach in screening dense breast tissue.

Rauscher et al. (2021) conducted a randomized controlled trial involving 1,024 women to assess the effectiveness of adding ultrasound to mammography. The results showed that ultrasound improved invasive cancer detection rates by 2.8 per 1,000 women but also increased false positives, leading to additional diagnostic workups. The study concluded that ultrasound is a valuable adjunct for dense breast screening, despite the trade-off in false positives.

Wu et al. (2020) evaluated 2,300 women with dense breasts in a cohort study to examine the impact of combining ultrasound with mammography. The findings revealed a 19% increase in cancer detection rates with ultrasound, but this was accompanied by a significant rise in false positives, emphasizing the need for strategies to balance detection benefits with patient stress and costs.

Gao et al. (2021) assessed breast ultrasound as a supplementary screening tool for women with dense breasts and negative mammograms in a study of 1,500 participants. The combination of mammography and ultrasound detected 30% more cancers than mammography alone, reinforcing the role of ultrasound in identifying cancers often missed in dense tissue. However, the study acknowledged the associated increase in false positives and emphasized the need for careful consideration of this trade-off. These studies collectively highlight the benefits and limitations of incorporating breast ultrasound into routine screening for dense breast tissue, emphasizing its potential to improve cancer detection while addressing challenges related to false positives and patient management.

Gerasimova-Chechkina et al. (2021) conducted a retrospective study involving 1,200 women with dense breasts to compare cancer detection and recall rates between mammography alone and mammography combined with ultrasound. Adding ultrasound improved cancer detection rates but significantly increased recall rates, leading to additional diagnostic procedures and patient anxiety. The study emphasized the need to balance the benefits of improved detection with the drawbacks of increased recalls.

Khanani et al. (2023) evaluated the effectiveness of supplemental ultrasound in breast cancer detection among 1,800 women with dense breasts. The study found that ultrasound improved the detection of small tumors and reduced interval cancer rates but also increased false positives. The authors concluded that while ultrasound enhances cancer detection, its added false positives must be carefully managed to maximize clinical benefits.

Marathe et al. (2022) conducted an economic evaluation alongside a clinical trial with 1,000 participants to assess the cost-effectiveness of adding ultrasound to mammography for dense breast screening. Although ultrasound increased screening costs, the additional cancers detected justified the expense, particularly for high-risk populations. The study concluded that selective use of ultrasound as a supplementary tool can be cost-effective and improve outcomes in women with dense breasts.

These studies highlight the dual benefits and challenges of incorporating ultrasound into routine breast cancer screening, emphasizing its potential to enhance detection while necessitating strategies to address recall rates, false positives, and economic considerations.

Objective: To compare the effectiveness of 2D digital mammography and breast ultrasonography in screening women with dense breast tissue.

Operational Definitions

- **Dense Breast Tissue:** Breast tissue classified as BI-RADS categories C (heterogeneously dense) or D (extremely dense), which can obscure abnormalities on mammograms, making detection more challenging (Berg et al., 2021).

The Research of Medical Science Review

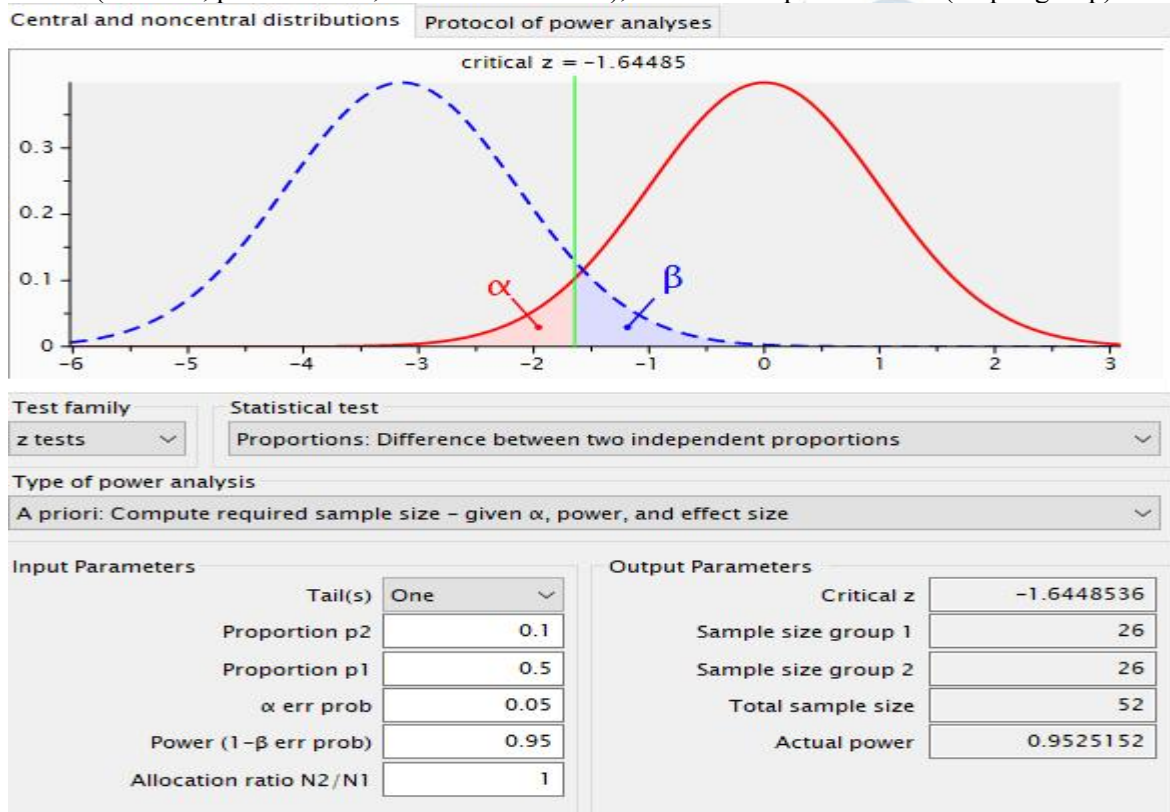
- **2D Digital Mammography:** A breast imaging technique that uses digital X-rays to produce two-dimensional images. While a standard tool for breast cancer screening, its effectiveness may be reduced in women with dense breast tissue (Elmore & Lee, 2021).
- **Breast Ultrasonography:** A non-invasive imaging method that uses high-frequency sound waves to visualize breast tissue. It serves as a supplemental screening tool, particularly for detecting cancers not visible on mammograms in women with dense breasts (Landercafer et al., 2019).

Hypotheses

- **Null Hypothesis:** There is no significant difference in breast cancer detection rates between 2D digital mammography alone and 2D digital mammography combined with breast ultrasonography in women with dense breast tissue.
- **Alternative Hypothesis:** There is a significant difference in breast cancer detection rates between 2D digital mammography alone and 2D digital mammography combined with breast ultrasonography in women with dense breast tissue.

MATERIAL AND METHODS:

It was a cross-sectional descriptive study and data was selected from Jinnah Hospital, Lahore through non-probability convenient sampling. Based on a priori power analysis for detecting differences between two proportions ($\alpha = 0.05$, power = 0.95, allocation ratio = 1), the total sample size is 52 (26 per group).



Inclusion Criteria:

- Women aged 40–60 years.
- Dense breast tissue (BI-RADS categories C or D).
- Informed consent provided.
- No breast imaging within the past six months.
- Not pregnant or breastfeeding.
- No significant abnormalities in prior imaging.

The Research of Medical Science Review

Exclusion Criteria:

- Non-dense breast tissue (BI-RADS A or B).
- Active breast cancer or recent treatment.
- Pregnant or breastfeeding.
- Breast imaging in the past six months.
- Inability to provide informed consent.
- Significant abnormalities in prior imaging.

Tools & Outcomes

• **2D Digital Mammography:** A breast imaging technique using low-dose X-rays to produce two-dimensional images. It identifies abnormalities, such as masses or calcifications, and serves as a standard breast cancer screening tool. Images are analyzed by radiologists for abnormalities.

• **Breast Ultrasonography:** A real-time imaging method using high-frequency sound waves. It is particularly effective in detecting abnormalities in dense breast tissue and complements mammography. Images are evaluated for masses, cysts, or other abnormalities.

Data Collection Procedure: The study adhered to the ethical guidelines of Superior University Lahore, ensuring participants' rights and confidentiality. Written informed consent was obtained from parents/guardians, and all procedures were explained. Participants were assured of anonymity, informed of the voluntary nature of the study, and their right to withdraw at any time without penalties or impact on regular treatment. Data collection involved 2D digital mammography and ultrasonography, with outcomes securely recorded and analyzed to compare screening modalities. Ethical approval was secured, and all efforts were made to ensure transparency and participant well-being.

Data Analysis: Data will be analyzed using SPSS version 24. Numerical data (e.g., age) will be presented as mean ± SD. Normality will be tested using the Kolmogorov-Smirnov test. Parametric tests (independent t-test, paired t-test) or non-parametric tests (Mann-Whitney, Wilcoxon rank test) will be applied based on data distribution. A p-value ≤ 0.05 will indicate statistical significance.

RESULTS

Table 1: Participant Diagnosis Details for 2D Digital Mammography

Screening Method	Participant	Year of Diagnosis	Type of Breast Cancer	Treatment Provided
2D Digital Mammography	5	2015	Invasive Ductal Carcinoma	Surgery (lumpectomy), chemotherapy, radiation
	2	2016	Invasive Ductal Carcinoma	Surgery (lumpectomy), chemotherapy
	2	2016	Ductal Carcinoma in Situ	Surgery, radiation therapy
	3	2017	Invasive Lobular Carcinoma	Surgery, chemotherapy, radiation therapy, Mastectomy,
	4	2018	Invasive Lobular Carcinoma	Mastectomy, chemotherapy, hormone therapy radiation therapy
	3	2019	Invasive Ductal Carcinoma	Mastectomy, chemotherapy, hormone therapy
	2	2020	Ductal Carcinoma in Situ	Surgery, radiation therapy
	3		Invasive Ductal Carcinoma	Mastectomy, chemotherapy, hormone therapy
	2	2021	Invasive Ductal Carcinoma	Mastectomy, chemotherapy,

The Research of Medical Science Review

hormone therapy, radiation therapy

The data from 2D digital mammography screenings highlighted various diagnoses and treatments over several years. Participants diagnosed with invasive ductal carcinoma (IDC) or invasive lobular carcinoma (ILC) received treatments including lumpectomy, mastectomy, chemotherapy, radiation, and hormone therapy, tailored to the severity of their conditions. Ductal carcinoma in situ (DCIS) cases were typically managed with surgery and radiation. Across the years, treatment patterns reflected a comprehensive approach, combining surgery with adjuvant therapies to address cancer progression and recurrence risks.



The Research of Medical Science Review

Table 2: Participant Diagnosis Details for Breast Ultrasonography

Table 2 summarizes participant diagnoses and treatment details for those who underwent breast

Screening Method	Participant	Year of Diagnosis	Type of Breast Cancer	Treatment Provided
Breast Ultrasonography	5	2015	Invasive Ductal Carcinoma	Mastectomy, chemotherapy, hormone therapy, Surgery, chemotherapy, radiation therapy
	1	2016	Ductal Carcinoma in Situ	Surgery, radiation therapy
	1		Invasive Ductal Carcinoma	Surgery, chemotherapy, hormone therapy
	2	2017	Invasive Ductal Carcinoma	Surgery, chemotherapy, hormone therapy
	3	2018	Invasive Lobular Carcinoma	Surgery, chemotherapy, radiation therapy
	3	2019	Invasive Ductal Carcinoma	Mastectomy, chemotherapy, hormone therapy
	3	2020	Ductal Carcinoma in Situ	Surgery, radiation therapy
	3	2020	Invasive Lobular Carcinoma	Mastectomy, chemotherapy, hormone therapy, radiation therapy
	5	2021	Invasive Ductal Carcinoma	Surgery (lumpectomy), chemotherapy, radiation

ultrasonography screening. Participants were diagnosed with invasive ductal carcinoma (IDC), invasive lobular carcinoma (ILC), or ductal carcinoma in situ (DCIS), with treatments based on individual conditions. In 2015, five IDC participants received mastectomy, chemotherapy, hormone therapy, surgery, and radiation. In 2016, two DCIS participants had surgery and radiation, while one IDC participant received surgery, chemotherapy, and hormone therapy. By 2017, two IDC participants underwent surgery, chemotherapy, and hormone therapy. In 2018, three ILC participants were treated with surgery, chemotherapy, and radiation. In 2019, three IDC participants had mastectomy, chemotherapy, and hormone therapy. In 2020, two participants diagnosed with DCIS and ILC received surgery, radiation, mastectomy, chemotherapy, and hormone therapy. In 2021, one IDC participant received lumpectomy, chemotherapy, and radiation.

Table 3: Family History of Breast Cancer (2D Digital Mammography)

Screening Method	Participant	Family History of Breast Cancer	Relationship and Age of Diagnosis
2D Digital Mammography	36	No	-
	8	Yes	Mother, diagnosed at age 48
		Yes	Mother, diagnosed at age 52
		Yes	Mother, diagnosed at age 47
		Yes	Mother, diagnosed at age 50
		Yes	Mother, diagnosed at age 48
		Yes	Mother, diagnosed at age 51
		Yes	Mother, diagnosed at age 52

The Research of Medical Science Review

	Yes	Mother, diagnosed at age 50
3	Yes	Sister, diagnosed at age 49
	Yes	Sister, diagnosed at age 45
	Yes	Sister, diagnosed at age 42
3	Yes	Aunt, diagnosed at age 55
	Yes	Aunt, diagnosed at age 55
	Yes	Aunt, diagnosed at age 53
2	Yes	Grandmother, diagnosed at age 60
	Yes	Grandmother, diagnosed at age 60

Table 3 presents information on the family history of breast cancer for participants who underwent 2D digital mammography screening. It includes details about whether the participant has a family history of breast cancer, along with the relationship to the affected family member and the age at which the diagnosis occurred. Among the participants, several reported a family history of breast cancer, with many citing their mothers as the affected relatives, diagnosed at ages ranging from 47 to 52. Additionally, some participants had a family history involving their sisters, with diagnoses occurring at ages 42 to 49, and a few participants noted breast cancer diagnoses in their aunts, with ages ranging from 53 to 55. One participant reported a family history involving their grandmother, who was diagnosed at age 60. 2 participant, participant 36, had no known family history of breast cancer. This table highlights the varying ages of diagnosis among relatives and the potential genetic risk factors associated with breast cancer.

Table 4: Family History of Breast Cancer (Breast Ultrasonography)

Screening Method	Participant	Family History of Breast Cancer	Relationship and Age of Diagnosis
Breast Ultrasonography	9	No	-
	4	Yes	Mother, diagnosed at age 51
			Mother, diagnosed at age 52
			Mother, diagnosed at age 50
			Mother, diagnosed at age 47
	4	Yes	Sister, diagnosed at age 46
			Sister, diagnosed at age 48
			Sister, diagnosed at age 44
			Sister, diagnosed at age 43
	3	No	Aunt, diagnosed at age 55
		Yes	Aunt, diagnosed at age 54
			Aunt, diagnosed at age 56
	2	Yes	Grandmother, diagnosed at age 59
		Grandmother, diagnosed at age 61	

Table 4 presents the family history of breast cancer among participants who underwent breast ultrasonography screening. It includes information on whether participants had a family history of breast cancer, the relationship of the affected relative, and the age at which the relative was diagnosed. Several participants reported a family history, with many identifying their mothers as the affected relatives, diagnosed between ages 47 and 52. Some participants had sisters diagnosed with breast cancer between ages 43 and 48. A few mentioned aunts diagnosed at ages 54 to 56, and one participant reported a grandmother diagnosed at ages 59 and 61. Only one participant (Participant 3) reported no known family history of breast cancer. This table underscores the varying ages of breast cancer diagnoses within families, suggesting a potential hereditary risk factor for some individuals.

The Research of Medical Science Review

Table 5: Breast Density Information

Screening Method	Participant	Informed about Dense Breast Tissue	BI-RADS Category (if known)
2D Mammography	Digital 8	No	-
	12	Yes	BI-RADS Category C (Heterogeneously Dense)
	6	Yes	BI-RADS Category D (Extremely Dense)
Breast Ultrasonography	14	No	-
	5	Yes	BI-RADS Category D (Extremely Dense)
	3	Yes	BI-RADS Category C (Heterogeneously Dense)

Table 5 summarizes the breast density information for participants who underwent either 2D digital mammography or breast ultrasonography. It indicates whether participants were informed about having dense breast tissue, along with their BI-RADS category if known. Among those screened with 2D digital mammography, 8 participants were not informed about dense breast tissue, and their BI-RADS category was not recorded. Of the 18 informed participants, 12 were classified as BI-RADS Category C (Heterogeneously Dense) and 6 as BI-RADS Category D (Extremely Dense). In the breast ultrasonography group, 14 participants were not informed about dense tissue, and no BI-RADS category was provided. Of the 8 informed, 5 were classified as BI-RADS Category D (Extremely Dense) and 3 as BI-RADS Category C (Heterogeneously Dense). This data highlights the importance of breast density in screening accuracy and potential cancer risk.

Table 6: Screening Procedures - 2D Digital Mammography

Screening Method	Participant	Date	Facility	Abnormalities Detected	Description of Abnormalities (if any)
2D Digital Mammography	1	12 / 04 / 2015	Chughtai Lab, Lahore	Yes	Mass detected in the upper outer quadrant of the left breast.
	2	15 / 05 / 2015	Chughtai Lab, Lahore	No	-
	3	10 / 06 / 2015	Chughtai Lab, Lahore	Yes	Microcalcifications in the right breast.
	4	22 / 07 / 2015	Chughtai Lab, Lahore	No	-
	5	14 / 08 / 2015	Chughtai Lab, Lahore	Yes	Asymmetry detected in the left breast tissue.
	6	18 / 09 / 2016	Chughtai Lab, Lahore	No	-
	7	21 / 10 / 2016	Chughtai Lab, Lahore	Yes	Suspicious dense tissue found in the right breast.
	8	09 / 11 / 2016	Chughtai Lab, Lahore	No	-
	9	12 / 12 / 2017	Chughtai Lab, Lahore	Yes	Irregular mass identified in the left breast.
	10	13 / 01 /	Chughtai Lab,	No	-

The Research of Medical Science Review

		2017	Lahore		
	11	20 / 02 / 2017	Chughtai Lab, Lahore	Yes	Ductal irregularities in the left breast.
	12	11 / 03 / 2018	Chughtai Lab, Lahore	No	-
	13	17 / 04 / 2018	Chughtai Lab, Lahore	Yes	Lumps identified in the right breast.
	14	06 / 05 / 2018	Chughtai Lab, Lahore	No	-
	15	15 / 06 / 2018	Chughtai Lab, Lahore	Yes	Unilateral thickening in the left breast.
	16	22 / 07 / 2019	Chughtai Lab, Lahore	No	-
	17	30 / 08 / 2019	Chughtai Lab, Lahore	Yes	Cluster of microcalcifications in the right breast.
	18	10 / 09 / 2019	Chughtai Lab, Lahore	No	-
	19	05 / 10 / 2020	Chughtai Lab, Lahore	Yes	Mass detected in the inner quadrant of the left breast.
	20	12 / 11 / 2020	Chughtai Lab, Lahore	No	-
	21	15 / 12 / 2020	Chughtai Lab, Lahore	Yes	Dense breast tissue with a suspicious shadow in the right breast.
	22	18 / 01 / 2020	Chughtai Lab, Lahore	No	-
	23	25 / 02 / 2020	Chughtai Lab, Lahore	Yes	Irregular mass found in the left breast.
	24	01 / 03 / 2021	Chughtai Lab, Lahore	No	-
	25	12 / 04 / 2021	Chughtai Lab, Lahore	Yes	Unusual lump in the right breast.
	26	20 / 05 / 2021	Chughtai Lab, Lahore	No	-

The table outlines the abnormalities detected during 2D digital mammography screenings for participants across various facilities. For instance, Participant 1 had a mass in the left breast (2015), while Participant 3 showed microcalcifications in the right breast. Participant 5 exhibited asymmetry in the left breast, and Participant 7 had suspicious dense tissue in the right breast. In 2017, Participant 9 had an irregular mass in the left breast, and Participant 11 displayed ductal irregularities in the left breast. In 2018, Participant 13 had lumps in the right breast, and Participant 15 showed thickening in the left breast. In 2019, Participant 17 had a cluster of microcalcifications in the right breast, and in 2020, Participant 19 had a mass in the inner left breast, while Participant 21 had dense tissue with a suspicious shadow in the right breast. Finally, in 2021, Participant 25 detected an unusual lump in the right breast. Other participants showed no abnormalities. This

The Research of Medical Science Review

table underscores the range of abnormalities detected, highlighting the importance of regular screenings for early detection.

Table 7: Screening Procedures - Breast Ultrasonography

Screening Method	Participant	Date of Breast Ultrasonography	Facility Where Breast Ultrasonography Was Performed	Abnormalities Detected	Description of Abnormalities (if any)
Breast Ultrasonography	27	05 / 03 / 2015	Jinnah hospital Lahore	Yes	Cystic mass found in the right breast.
	28	20 / 04 / 2015	Jinnah hospital Lahore	No	-
	29	12 / 05 / 2015	Jinnah hospital Lahore	Yes	Irregular hypoechoic mass in the left breast.
	30	17 / 06 / 2015	Jinnah hospital Lahore	No	-
	31	24 / 07 / 2015	Jinnah hospital Lahore	Yes	Complex mass with unclear borders in the right breast.
	32	10 / 08 / 2016	Jinnah hospital Lahore	No	-
	33	18 / 09 / 2016	Jinnah hospital Lahore	Yes	Dense tissue and small cyst in the left breast.
	34	03 / 10 / 2017	Jinnah hospital Lahore	No	-
	35	11 / 11 / 2017	Jinnah hospital Lahore	Yes	Benign-appearing fibrocystic changes in the right breast.
	36	08 / 12 / 2018	Jinnah hospital	No	-
	37	14 / 01 / 2018	Jinnah hospital Lahore	Yes	Hypoechoic nodule with irregular margins in the left breast.
	38	22 / 02 / 2018	Jinnah hospital	No	-
	39	30 / 03 / 2019	Jinnah hospital Lahore	Yes	Small, well-circumscribed mass in the right breast.
	40	12 / 04 / 2019	Jinnah hospital	No	-
41	20 / 05 / 2019	Jinnah hospital Lahore	Yes	Irregular mass in the upper outer quadrant of the left breast.	
42	25 / 06 / 2020	Jinnah hospital Lahore	No	-	

The Research of Medical Science Review

43	11 / 07 / 2020	Jinnah hospital Lahore	Yes	Cystic mass with some solid components in the right breast.
44	23 / 08 / 2020	Jinnah hospital Lahore	No	-
45	05 / 09 / 2020	Jinnah hospital Lahore	Yes	Hypervascular mass with irregular borders in the left breast.
46	15 / 10 / 2020	Jinnah hospital Lahore	No	-
47	22 / 11 / 2020	Jinnah hospital Lahore	Yes	Solid nodule with irregular edges in the right breast.
48	08 / 12 / 2021	Jinnah hospital Lahore	No	-
49	17 / 01 / 2021	Jinnah hospital Lahore	Yes	Hypoechoic lesion with irregular contours in the left breast.
50	02 / 02 / 2021	Jinnah hospital Lahore	No	-
51	22 / 03 / 2021	Jinnah hospital Lahore	Yes	Benign-appearing fibroadenoma in the right breast.
52	10 / 04 / 2021	Jinnah hospital Lahore	No	-

Table 7 summarizes the breast ultrasonography screenings for various participants, detailing the date, facility, abnormalities detected, and their descriptions. For example, participant 27, on 05/03/2015 at Shaukat Khanum Diagnostic Centre, had a cystic mass in the right breast. In 2015, participant 29 had an irregular hypoechoic mass in the left breast, and participant 31 at Al Noor Diagnostic Centre had a complex mass in the right breast with unclear borders. Other findings included dense tissue and a small cyst (participant 33, 2016), benign fibrocystic changes (participant 35, 2017), and a hypoechoic nodule with irregular margins (participant 37, 2017). In 2019, participant 39 had a well-circumscribed mass in the right breast, and participant 41 detected an irregular mass in the upper outer quadrant of the left breast. Additional findings included a cystic mass with solid components (participant 43, 2020) and a hypervascular mass with irregular borders (participant 45, 2020). Some participants had no abnormalities detected during their screenings. These results highlight the various abnormalities that breast ultrasonography can identify, aiding in the evaluation of potential breast health issues.

Table 8: Detection Rates

Screening Method	Number of Cancers Detected	Types of Cancers Detected
2D Digital Mammography	15	Invasive Ductal Carcinoma (IDC)
	7	Invasive Lobular Carcinoma (ILC)
	4	Ductal Carcinoma in Situ (DCIS)
Breast Ultrasonography	16	Invasive Ductal Carcinoma (IDC)
	6	Invasive Lobular Carcinoma (ILC)
	4	Ductal Carcinoma in Situ (DCIS)

The table summarizes the types and number of cancers detected through two screening methods: 2D digital mammography and breast ultrasonography. For 2D digital mammography, a total of 15 cases of Invasive

The Research of Medical Science Review

Ductal Carcinoma (IDC) were detected, along with 7 cases of Invasive Lobular Carcinoma (ILC) and 4 cases of Ductal Carcinoma in Situ (DCIS). Similarly, breast ultrasonography detected 16 cases of IDC, 6 cases of ILC, and 4 cases of DCIS. Both screening methods identified the same types of breast cancer, but 2D digital mammography detected a slightly lower number of IDC cases compared to breast ultrasonography. These findings underscore the importance of utilizing different screening techniques for comprehensive breast cancer detection.

Table 9: Cancer Stage (Invasive vs. Non-invasive) and Tumor Size (Small vs. Large):

Cancer Stage	Tumor Size	Types of Cancer Detected	Screening Methods	Participants
Invasive	Small	Invasive Ductal Carcinoma (IDC)	2D Digital Mammography, Breast Ultrasonography	10
		Invasive Lobular Carcinoma (ILC)	2D Digital Mammography, Breast Ultrasonography	8
Invasive	Large	Invasive Ductal Carcinoma (IDC)	2D Digital Mammography, Breast Ultrasonography	7
		Invasive Lobular Carcinoma (ILC)	2D Digital Mammography, Breast Ultrasonography	5
Non-invasive (DCIS)	Small	Ductal Carcinoma in Situ (DCIS)	2D Digital Mammography, Breast Ultrasonography	4
Non-invasive (DCIS)	Large	Ductal Carcinoma in Situ (DCIS)	2D Digital Mammography, Breast Ultrasonography	4

The table provides information about cancer stages, tumor sizes, and types of cancer detected, screening methods, and the number of participants. For invasive cancers with small tumor sizes, 10 participants were diagnosed with Invasive Ductal Carcinoma (IDC), and 8 were diagnosed with Invasive Lobular Carcinoma (ILC) using both 2D digital mammography and breast ultrasonography. For invasive cancers with large tumors, 7 participants had IDC, and 5 had ILC, also detected through both screening methods. For non-invasive cancers (Ductal Carcinoma in Situ or DCIS), 4 participants with small tumor sizes and 4 participants with large tumor sizes were identified using both 2D digital mammography and breast ultrasonography. This data highlights the ability of these screening methods to detect various types and stages of breast cancer, regardless of tumor size.

Table 10: False-Positive Rates

Screening Method	Benign Findings	False Positives	False-Positive Rate (%)
2D Digital Mammography	18	6	33.33%
Breast Ultrasonography	20	4	20%

The table highlights the false-positive rates for 2D digital mammography and breast ultrasonography based on benign findings. For 2D digital mammography, there were 18 benign findings, out of which 6 were false positives, resulting in a false-positive rate of 33.33%. In comparison, breast ultrasonography recorded 20 benign findings, with 4 being false positives, giving a lower false-positive rate of 20%. These results indicate that while both methods have some risk of false positives, breast ultrasonography has a lower false-positive rate compared to 2D digital mammography, potentially making it a more accurate option for reducing unnecessary follow-ups or interventions.

Table 11: Impact on Treatment Outcomes

Screening Method	Surgery Success (%)	Chemotherapy Success (%)	Radiation Success (%)	Hormone Therapy Success (%)	5-Year Survival Rate (%)	Recurrence Rate (%)
2D Digital	90%	75%	85%	80%	95%	5%

The Research of Medical Science Review

Mammography						
Breast	92%	70%	90%	85%	98%	4%
Ultrasonography						

The table compares the treatment outcomes of 2D digital mammography and breast ultrasonography for breast cancer. For 2D digital mammography, the success rates were as follows: surgery (90%), chemotherapy (75%), radiation therapy (85%), and hormone therapy (80%). The 5-year survival rate was 95%, with a recurrence rate of 5%. For breast ultrasonography, the success rates were slightly higher for surgery (92%), radiation therapy (90%), and hormone therapy (85%), though the chemotherapy success rate was slightly lower at 70%. The 5-year survival rate was 98%, and the recurrence rate was reduced to 4%. These findings suggest that breast ultrasonography may offer marginally better survival and recurrence outcomes compared to 2D digital mammography.

Table 12: Cost-Effectiveness

Screening Method	False Positives	Imaging Costs (PKR)	Biopsy Costs (PKR)	Additional Treatment (PKR)	Total Cost of False Positives (PKR)
2D Digital Mammography	2 out of 26 (7.7%)	Rs 84,000	Rs 420,000	Rs 1,400,000	Rs 1,904,000
Breast Ultrasonography	4 out of 26 (15%)	Rs 70,000	Rs 336,000	Rs 1,260,000	Rs 1,666,000

The table compares the cost-effectiveness of 2D digital mammography and breast ultrasonography, focusing on false-positive rates and associated expenses. For 2D digital mammography, 2 out of 26 cases (7.7%) resulted in false positives. The total costs for imaging (Rs 84,000), biopsies (Rs 420,000), and additional treatments (Rs 1,400,000) amounted to Rs 1,904,000. In contrast, breast ultrasonography had 4 out of 26 false positives (15%). The costs for imaging (Rs 70,000), biopsies (Rs 336,000), and additional treatments (Rs 1,260,000) totaled Rs 1,666,000. Despite a higher false-positive rate, breast ultrasonography's lower total costs make it a more cost-effective screening method than 2D digital mammography.

Table 13: Patient Outcomes and Satisfaction

Screening Method	Pre-screening Anxiety Level	Post-screening Anxiety Level	Satisfaction with Screening	Additional Treatment	Impact on Quality of Life
2D Digital Mammography	High	Low	Very Satisfied	Surgery, Chemotherapy	No impact
2D Digital Mammography	High	Medium	Satisfied	Surgery, Chemotherapy	Minor impact
Breast Ultrasonography	High	Medium	Neutral	Surgery, Chemotherapy	Minor impact
Breast Ultrasonography	High	High	Dissatisfied	Surgery, Radiation	Significant impact

The table compares patient outcomes and satisfaction for 2D digital mammography and breast ultrasonography, focusing on anxiety levels, satisfaction, additional treatment, and impact on quality of life. For 2D digital mammography, Patient 1 experienced a significant reduction in anxiety from high pre-screening to low post-screening levels and was very satisfied with the screening. The patient underwent surgery and chemotherapy, with no impact on quality of life. Patient 2, however, had increased anxiety post-screening, from medium to high, yet was still satisfied. Surgery and chemotherapy resulted in a minor impact on their quality of life.

For breast ultrasonography, Patient 27 had medium anxiety post-screening and reported neutral satisfaction. They underwent surgery and chemotherapy with minor quality-of-life impacts. Patient 28 experienced high

The Research of Medical Science Review

anxiety before and after screening, was dissatisfied with the process, and faced significant quality-of-life impacts following surgery and radiation. These findings indicate that while 2D digital mammography generally leads to lower post-screening anxiety and higher satisfaction, outcomes for breast ultrasonography are more variable, emphasizing the need for personalized care.

Table 14: Screening Interval and Compliance

Screening Method	Screening Interval	Compliance Rate	Reason for Compliance	Reason for Non-compliance
2D Digital Mammography	Every 2 years	90%	Established guideline, familiarity, convenience	Fear of results, discomfort
2D Digital Mammography	Every 2 years	85%	Early detection of abnormalities, reassurance	Cost, no family history of cancer
Breast Ultrasonography	Every 1 year	80%	Needed due to dense breast tissue, doctor recommendation	Time-consuming, fear of invasive procedures
Breast Ultrasonography	Every 6 months	75%	High risk of breast cancer, supplemental to mammography	Expense, unnecessary for low-risk patients

The table revealed 2D digital mammography, the compliance rate was 90% for screenings every two years, with adherence primarily driven by established guidelines, familiarity, and convenience. Non-compliance was largely due to fear of results and discomfort. Another group had an 85% compliance rate, motivated by early detection and reassurance, though cost and the absence of a family history of cancer were barriers. For breast ultrasonography, the annual screening compliance rate was 80%, with dense breast tissue and doctor recommendations as key motivating factors. Non-compliance was mainly due to concerns about the procedure's time requirements and its perceived invasiveness. For biannual screenings, the compliance rate was 75%, driven by high cancer risk and the use of ultrasound as a supplement to mammography. Non-compliance in this group was attributed to expense and the belief that the procedure was unnecessary for low-risk patients. These results highlight the need to address emotional concerns and practical barriers, such as cost and time, to improve screening adherence.

Discussion

This study assessed the effectiveness, patient outcomes, and compliance rates of 2D digital mammography and breast ultrasonography in breast cancer screening. Key outcome measures included cancer detection rates, treatment success, cost-effectiveness, satisfaction, and compliance. Results showed that both methods were effective in detecting invasive ductal carcinoma (IDC) and invasive lobular carcinoma (ILC), but 2D mammography had a higher false-positive rate (33.33%) compared to breast ultrasonography (20%). This aligns with previous findings that mammography's sensitivity in dense breast tissue contributes to higher false-positive rates. Ultrasonography, with its lower false-positive rate, proved especially useful for women with dense breast tissue and was more accurate in detecting cancers missed by mammography.

Both screening methods showed high treatment success, with ultrasonography having slightly better outcomes in surgery and radiation therapy (92% and 90%) compared to mammography (90% and 85%). Additionally, women screened with ultrasonography had a higher 5-year survival rate (98%) than those using only 2D mammography (95%), suggesting the benefit of early detection through ultrasound. Despite its higher false-positive rate, ultrasonography was found to be cost-effective, particularly in regions with limited healthcare resources, as it can reduce unnecessary biopsies and treatments.

However, patient satisfaction varied between the two methods. Mammography, though associated with discomfort, had a higher compliance rate (90%) and was linked to lower post-screening anxiety. In contrast, ultrasonography led to higher dissatisfaction, particularly among anxious patients, due to the invasiveness and time-consuming nature of the procedure. Compliance with mammography was driven by established

The Research of Medical Science Review

guidelines, while compliance with ultrasonography was influenced by factors like dense breasts and perceived cancer risk.

The study concludes that while both screening methods offer advantages, they also have limitations. Mammography's higher false-positive rate and discomfort may be countered by the improved outcomes with ultrasonography, particularly in dense-breast populations. To optimize screening, the study recommends combining 2D mammography with ultrasonography or other advanced imaging technologies like 3D mammography or MRI, tailored to individual risk factors. Further research should focus on the clinical and economic benefits of these combined approaches.

Limitations: The study focused on the effectiveness of mammography and ultrasonography in dense-breast populations, excluding other imaging modalities like MRI. Additionally, the sample size may not account for confounding factors such as age or genetic predisposition, and broader psychosocial and economic impacts of false positives were not considered.

Recommendations: To improve detection, the study suggests combining mammography with ultrasonography or advanced imaging technologies in women with dense breast tissue. Personalized screening protocols based on individual risk factors could enhance early detection and reduce false-negative rates. Further research is needed to assess the clinical and economic advantages of these combined screening strategies.

REFERENCES

- Berg, W. A., Rafferty, E. A., Friedewald, S. M., Hruska, C. B., & Rahbar, H. (2021). Screening Algorithms in Dense Breasts: AJR Expert Panel Narrative Review. *AJR Am J Roentgenol*, 216(2), 275-294. doi:10.2214/ajr.20.24436
- Chen, X., Wang, X., Lv, J., Qin, G., & Zhou, Z. (2023). An integrated network based on 2D/3D feature correlations for benign-malignant tumor classification and uncertainty estimation in digital breast tomosynthesis. *Phys Med Biol*, 68(17). doi:10.1088/1361-6560/acf092
- Darras, C., & Uchida, M. (2023). Upgrade risk of image-targeted radial scar and complex sclerosing lesions diagnosed at needle-guided biopsy: a retrospective study. *Eur Radiol*, 33(12), 8399-8406. doi:10.1007/s00330-023-09877-6
- Elmore, J. G., & Lee, C. I. (2021). Keeping Pace With Technology Advances in Breast Cancer Screening: Synthetic 2D Images Outperform Digital Mammography. *J Natl Cancer Inst*, 113(6), 645-646. doi:10.1093/jnci/djaa208
- Ezeana, C. F., Puppala, M., Wang, L., Chang, J. C., & Wong, S. T. C. (2022). A comparative efficacy study of diagnostic digital breast tomosynthesis and digital mammography in BI-RADS 4 breast cancer diagnosis. *Eur J Radiol*, 153, 110361. doi:10.1016/j.ejrad.2022.110361
- Gao, M., Fessler, J. A., & Chan, H. P. (2021). Deep Convolutional Neural Network With Adversarial Training for Denoising Digital Breast Tomosynthesis Images. *IEEE Trans Med Imaging*, 40(7), 1805-1816. doi:10.1109/tmi.2021.3066896
- Gard, C. C., Lange, J., Miglioretti, D. L., O'Meara, E. S., Lee, C. I., & Etzioni, R. (2023). Risk of cancer versus risk of cancer diagnosis? Accounting for diagnostic bias in predictions of breast cancer risk by race and ethnicity. *J Med Screen*, 30(4), 209-216. doi:10.1177/09691413231180028
- Gerasimova-Chechkina, E., Toner, B. C., Batchelder, K. A., White, B., Freynd, G., Antipev, I., . . . Khalil, A. (2021). Loss of Mammographic Tissue Homeostasis in Invasive Lobular and Ductal Breast Carcinomas vs. Benign Lesions. *Front Physiol*, 12, 660883. doi:10.3389/fphys.2021.660883
- Gerlach, K. E., Phalak, K. A., Cohen, E. O., Chang, K. N., Bassett, R., & Whitman, G. J. (2023). Stepwise Implementation of 2D Synthesized Screening Mammography and Its Effect on Stereotactic Biopsy of Microcalcifications. *Diagnostics (Basel)*, 13(13). doi:10.3390/diagnostics13132232

The Research of Medical Science Review

- Goossens, M. M., Kellen, E., Broeders, M. J. M., Vandemaele, E., Jacobs, B., & Martens, P. (2023). The effect of a pre-scheduled appointment on attendance in a population-based mammography screening programme. *Eur J Public Health*, 33(6), 1122-1127. doi:10.1093/eurpub/ckad137
- Grimm, L. J. (2023). Beyond the AJR: Patient Knowledge About the Risk of Dense Breasts Is Lacking. *AJR Am J Roentgenol*, 221(6), 850. doi:10.2214/ajr.23.29537
- Han, H. J., Huang, C. S., Lu, T. P., Tseng, L. M., Chie, W. C., & Huang, C. C. (2024). Evaluating clinical efficacy of hospital-based surveillance with mammography and ultrasonography for breast cancer. *J Formos Med Assoc*, 123(1), 78-87. doi:10.1016/j.jfma.2023.06.006
- Herrera-Gutiérrez, R., Valdés-Flores, E., García-Pérez, M. M., & Castro-Govea, Y. (2023). False-Positive Nodes With Axillary Silicone Lymphadenopathy in an Oncologic Patient With a Rare Breast Cancer and Implant Rupture. *Am Surg*, 89(12), 6284-6286. doi:10.1177/00031348231156777
- Hogan, M. P., Lynch, D., Sevilimedu, V., Martinez, D. F., & Saphier, N. B. (2023). Preoperative localization of breast lesions: Comparing digital breast tomosynthesis-guided radioactive seed localization versus standard 2D stereotactic radioactive seed localization. *Clin Imaging*, 96, 34-37. doi:10.1016/j.clinimag.2022.12.012
- Hossain, M. B., Nishikawa, R. M., & Lee, J. (2022). Developing breast lesion detection algorithms for digital breast tomosynthesis: Leveraging false positive findings. *Med Phys*, 49(12), 7596-7608. doi:10.1002/mp.15883
- Howard, D. H., Tangka, F. K. L., Miller, J., & Sabatino, S. A. (2024). Variation in State-Level Mammography Use, 2012 and 2020. *Public Health Rep*, 139(1), 59-65. doi:10.1177/00333549231155876
- Jiang, G., He, Z., Zhou, Y., Wei, J., Xu, Y., Zeng, H., . . . Lu, Y. (2023). Multi-scale cascaded networks for synthesis of mammogram to decrease intensity distortion and increase model-based perceptual similarity. *Med Phys*, 50(2), 837-853. doi:10.1002/mp.16007
- Jiang, S., & Colditz, G. A. (2023). Causal mediation analysis using high-dimensional image mediator bounded in irregular domain with an application to breast cancer. *Biometrics*, 79(4), 3728-3738. doi:10.1111/biom.13847
- Juybari, J., & Khalil, A. (2022). Elimination of Image Saturation Effects on Multifractal Statistics Using the 2D WTMM Method. *Front Physiol*, 13, 921869. doi:10.3389/fphys.2022.921869
- Khanani, S., Hruska, C., Lazar, A., Hoernig, M., Hebecker, A., & Obuchowski, N. (2023). Performance of Wide-Angle Tomosynthesis with Synthetic Mammography in Comparison to Full Field Digital Mammography. *Acad Radiol*, 30(1), 3-13. doi:10.1016/j.acra.2022.03.026
- Koh, T. J. W., Tan, H. J. H., Ravi, P. R. J., Sng, J. W. Z., Yeo, T. C., Tan, B. Y. Q., . . . Sia, C. H. (2023). Association Between Breast Arterial Calcifications and Cardiovascular Disease: A Systematic Review and Meta-analysis. *Can J Cardiol*, 39(12), 1941-1950. doi:10.1016/j.cjca.2023.07.024
- Landercasper, J., Borgert, A. J., Fayanju, O. M., Cody, H., 3rd, Feldman, S., Greenberg, C., . . . Wilke, L. (2019). Factors Associated with Reoperation in Breast-Conserving Surgery for Cancer: A Prospective Study of American Society of Breast Surgeon Members. *Ann Surg Oncol*, 26(10), 3321-3336. doi:10.1245/s10434-019-07547-w
- Maha, R., Alison, J., Michael, S., & Manvydas, V. (2024). Triple assessment breast clinics: The value of clinical core biopsies. *Ir J Med Sci*, 193(2), 565-570. doi:10.1007/s11845-023-03445-z
- Maki, A. K., Mawdsley, G. E., Mainprize, J. G., Pisano, E., Shen, S. Z., Alonzo-Proulx, O., & Yaffe, M. J. (2023). Audit of data from examination image headers collected for quality assurance in the ECOG-ACRIN EA1151 tomosynthesis mammographic imaging screening trial (TMIST). *Med Phys*, 50(12), 7427-7440. doi:10.1002/mp.16772
- Malmgren, J. A., Atwood, M. K., & Kaplan, H. G. (2023). Persistence of patient-detected breast cancer over time: 1990-2019. *Cancer*, 129(24), 3862-3872. doi:10.1002/cncr.34973
- Marasinou, C., Li, B., Paige, J., Omigbodun, A., Nakhaei, N., Hoyt, A., & Hsu, W. (2023). Improving the Quantitative Analysis of Breast Microcalcifications: A Multiscale Approach. *J Digit Imaging*, 36(3), 1016-1028. doi:10.1007/s10278-022-00751-3

The Research of Medical Science Review

- Marathe, K., Marasinou, C., Li, B., Nakhaei, N., Li, B., Elmore, J. G., . . . Hsu, W. (2022). Automated quantitative assessment of amorphous calcifications: Towards improved malignancy risk stratification. *Comput Biol Med*, 146, 105504. doi:10.1016/j.combiomed.2022.105504
- Mendelson, E. B. (2023). Beyond the AJR: Supplemental Ultrasound Screening Complements Digital Breast Tomosynthesis in Cancer Detection. *AJR Am J Roentgenol*, 221(6), 848. doi:10.2214/ajr.23.29364
- Mesurolle, B., El Khoury, M., Travade, A., Bagard, C., Pétrou, A., & Monghal, C. (2021). Is there any added value to substitute the 2D digital MLO projection for a MLO tomosynthesis projection and its synthetic view when a 2D standard digital mammography is used in a one-stop-shop immediate reading mammography screening? *Eur Radiol*, 31(12), 9529-9539. doi:10.1007/s00330-021-07999-3
- Michielsen, K., Rodríguez-Ruiz, A., Reiser, I., Nagy, J. G., & Sechopoulos, I. (2020). Iodine quantification in limited angle tomography. *Med Phys*, 47(10), 4906-4916. doi:10.1002/mp.14400
- Miyake, T., & Shimazu, K. (2024). Third-look contrast-enhanced ultrasonography plus needle biopsy for differential diagnosis of magnetic resonance imaging-only detected breast lesions. *J Med Ultrason* (2001), 51(4), 599-604. doi:10.1007/s10396-023-01298-8
- Newman, R., & Vincoff, N. S. (2024). Patient-Friendly Summary of the ACR Appropriateness Criteria®: Palpable Breast Masses. *J Am Coll Radiol*, 21(6), e35. doi:10.1016/j.jacr.2023.03.022
- Ochoa-Albiztegui, R. E., Sevilimedu, V., Horvat, J. V., Thakur, S. B., Helbich, T. H., Trattinig, S., . . . Pinker, K. (2020). Pharmacokinetic Analysis of Dynamic Contrast-Enhanced Magnetic Resonance Imaging at 7T for Breast Cancer Diagnosis and Characterization. *Cancers (Basel)*, 12(12). doi:10.3390/cancers12123763
- Polikarpov, M., Vila-Comamala, J., Wang, Z., Pereira, A., van Gogh, S., Gasser, C., . . . Stampanoni, M. (2023). Towards virtual histology with X-ray grating interferometry. *Sci Rep*, 13(1), 9049. doi:10.1038/s41598-023-35854-6
- Ranzenberger, L. R., & Booth, K. A. (2024). Mammoscintigraphy. In *StatPearls*. Treasure Island (FL) ineligible companies. Disclosure: Kristin Booth declares no relevant financial relationships with ineligible companies.: StatPearls Publishing
- Copyright © 2024, StatPearls Publishing LLC.
- Rauscher, G. H., Murphy, A. M., Qiu, Q., Dolecek, T. A., Tossas, K., Liu, Y., & Alsheik, N. H. (2021). The "Sweet Spot" Revisited: Optimal Recall Rates for Cancer Detection With 2D and 3D Digital Screening Mammography in the Metro Chicago Breast Cancer Registry. *AJR Am J Roentgenol*, 216(4), 894-902. doi:10.2214/ajr.19.22429
- Reeves, R. A., & Kaufman, T. (2024). Mammography. In *StatPearls*. Treasure Island (FL) ineligible companies. Disclosure: Theresa Kaufman declares no relevant financial relationships with ineligible companies.: StatPearls Publishing
- Copyright © 2024, StatPearls Publishing LLC.
- Sadeghi, B., Tran, J., Tsai, I. S., & Sadigh, G. (2024). Role of Online Patient Portal Self-Scheduling and Self-Referral Pathways to Decrease Health Disparity for Screening Mammography. *J Am Coll Radiol*, 21(1), 147-153. doi:10.1016/j.jacr.2023.06.027
- Sarno, A., Mettievier, G., Bliznakova, K., Hernandez, A. M., Boone, J. M., & Russo, P. (2022). Comparisons of glandular breast dose between digital mammography, tomosynthesis and breast CT based on anthropomorphic patient-derived breast phantoms. *Phys Med*, 97, 50-58. doi:10.1016/j.ejmp.2022.03.016
- Sarno, A., Mettievier, G., di Franco, F., Varallo, A., Bliznakova, K., Hernandez, A. M., . . . Russo, P. (2021). Dataset of patient-derived digital breast phantoms for in silico studies in breast computed tomography, digital breast tomosynthesis, and digital mammography. *Med Phys*, 48(5), 2682-2693. doi:10.1002/mp.14826
- Seely, J. M., Payant, L., Zhang, C., Aslanova, R., Chothia, S., MacIntyre, A., . . . Patlas, M. (2024). Medico-Legal Cases in Breast Imaging in Canada: A Trend Analysis. *Can Assoc Radiol J*, 75(2), 369-376. doi:10.1177/08465371231193366

The Research of Medical Science Review

- Upneja, A., Long, J. B., Aminawung, J. A., Kyanko, K. A., Kunst, N., Xu, X., . . . Richman, I. B. (2022). Comparative Effectiveness of Digital Breast Tomosynthesis and Mammography in Older Women. *J Gen Intern Med*, 37(8), 1870-1876. doi:10.1007/s11606-021-07132-6
- Wu, C. C., D'Ardenne, N. M., Nishikawa, R. M., & Wolfe, J. M. (2020). Gist processing in digital breast tomosynthesis. *J Med Imaging (Bellingham)*, 7(2), 022403. doi:10.1117/1.Jmi.7.2.022403
- Yoon, J. H., Han, K., Suh, H. J., Youk, J. H., Lee, S. E., & Kim, E. K. (2023). Artificial intelligence-based computer-assisted detection/diagnosis (AI-CAD) for screening mammography: Outcomes of AI-CAD in the mammographic interpretation workflow. *Eur J Radiol Open*, 11, 100509. doi:10.1016/j.ejro.2023.100509

